

Suction Cleaning of the External Auditory Canal in Otomycosis: Is it Really Helpful?

Muhammad Rafique, Iqbal Hussain Udaipurwala, Ehsan-ul-Haq

ABSTRACT

OBJECTIVE: This study was conducted with the objective to find out whether suction cleaning of the external auditory canal in cases of otomycosis is helpful or not.

STUDY DESIGN: Prospective, randomized comparative study

PLACE AND DURATION OF STUDY: This multi-center study conducted at the departments of ENT, head & neck surgery of Liaquat University Hospital, Hyderabad, Sheikh Zayed Hospital, Rahim Yar Khan and Zubaida Medical Centre, Karachi. The study was conducted from March 2013 to February 2014 for a period of one year.

PATIENT AND METHODS: A total of 200 patients were included in this study. These patients were serially divided into two groups A and B. Both groups received topical antifungal solution of 1% clotrimazole, 3 to 4 drops three times per day. In group A at the time of first consultation suction cleaning of the fungal debris was also done while in group B only above mentioned treatment was given without suction cleaning of the external auditory canal. All these patients were followed up regularly till the complete resolution of the disease.

RESULTS: The minimum time duration for group A was 5 days and for group B was 9 days. The maximum time duration for group A was 18 days while for group B was 23 days. The mean time duration for complete resolution in group A was 9.6 days while in group B was 15.2 days ($p < 0.05$).

CONCLUSION: Suction cleaning of the external auditory canal for removal of fungal debris is very helpful and it reduces the time duration for complete resolution. So it should be performed in every patient of otomycosis to remove fungal debris.

KEY WORDS: Otomycosis, fungal infection, aspergillosis, otitis externa.

INTRODUCTION

Otomycosis or fungal otitis externa is a very common condition throughout the globe with frequency varying in different parts¹. It is very much prevalent in tropics and sub-tropic regions². The frequency reported varies widely from 5 to 25 percent of the total cases of otitis externa³ or 6 to 9 percent of all otologic patients⁴. The prevalence of otomycosis is reported to be on increase because of indiscriminate use of antibiotic drops⁵. The common micro-organism responsible for this condition are different species of *Aspergillus* and *Candida albicans* andazole antifungal medication is very effective against these⁶.

Suction cleaning of the external auditory canal is considered as a part of the treatment along with antifungal ear drops. Most of the patients are very apprehensive and worried about this procedure; many of them even do not allow this procedure. Children, young females and anxious people are specially prone for this attitude and suction cleaning in these persons is a bit difficult and sometimes impossible. This study was conducted with the objective to find out whether this procedure is really of any benefit or this can be

avoided in people who are very hesitant about this procedure.

PATIENTS AND METHODS

This is a multi-center study conducted at the department of otorhinolaryngology and head & neck surgery of Liaquat University of Health & Medical Sciences, Jamshoro, Sheikh Zayed Medical College & Hospital, Rahim Yar Khan and Zubaida Medical Centre, Karachi. The study was conducted for a period of one year from March 2013 to February 2014. Inclusion criterion was patient diagnosed on clinical grounds as a case of uncomplicated otomycosis either in one ear or both ears. Exclusion criteria for this study were as follows:

- Patient with history of any immunocompromised condition like diabetes etc.
- Patient with history of discharge or chronic suppurative otitis media
- Patients with perforated ear drum
- Patient with history of mastoidectomy or other ear surgery
- Patients with clinical suspicion of bacterial otitis externa along with otomycosis

f. Children below the age of 16 years

The patients were divided into two groups A and B on serial basis i.e. according to its turn one patient in group A and then one patient in group B and so on. Informed consent of the patients were taken for inclusion in this study. After exclusion a total of 100 patients were included in each group. In group A, at the time of first consultation, thorough suction cleaning of the external auditory canal done in OPD while in group B no such cleaning was done. All the patients were given 1% clotrimazole solution to instill in the ear, 3 to 4 drops three time per day. All the patients were also advised to clean the ear with dry cotton bud before instilling the drop every time. They were advised to come in OPD for follow-up after every 3 to 4 days till the complete resolution of the condition. All the record was maintained on a specially designed performa and the data analysis was done on SPSS version 16 (p value of < 0.05 was considered significant).

RESULTS

A total of 200 patients were included in this study, being 100 patient in each group A and B. There were 113 male (56.5%) and 87 female (43.5%) patients with male to female ratio of 1.3: 1. Distribution of male and female patients in each group A and B is shown in table 1. The age ranges from 16 years to 74 years with mean age of 24.3 years (± 7.8 years). The mean age for group A was 22.9 years while for group B was 25.7 years (table 1). Involvement of one ear was present in 94 patients (47%) and both ears in 106 patients (53%). Table I also shows the involvement of one or two ears in each group A and B.

Figure I shows the time duration required for complete resolution of the disease. The minimum time duration for group A was 5 days and for group B was 9 days. The maximum time duration for group A was 18 days while for group B was 23 days. 2 patients recovered in 5 days or less and 23 patients between 6 to 8 days in group A while complete recovery during this time occurred in no patient in group B. All the patients in group A recovered completely till maximum of 18 days while in group B, 3 patients took more than 22 days

and 8 patients were between 19 to 21 days (Fig. I). Figure II depicts the mean duration of time required for complete resolution in both groups A and B, where it is 9.6 days in group A and 15.2 days in group B (p < 0.05). It clearly shows that the time duration was significantly lower in group A than group B.

FIGURE I: TIME OF RESOLUTION IN EACH GROUP (IN DAYS)

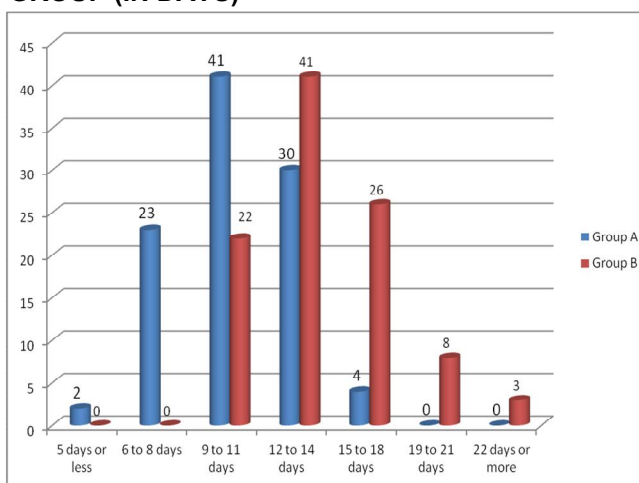


FIGURE II: MEAN DURATION OF RESOLUTION IN EACH GROUP A AND B (IN DAYS)

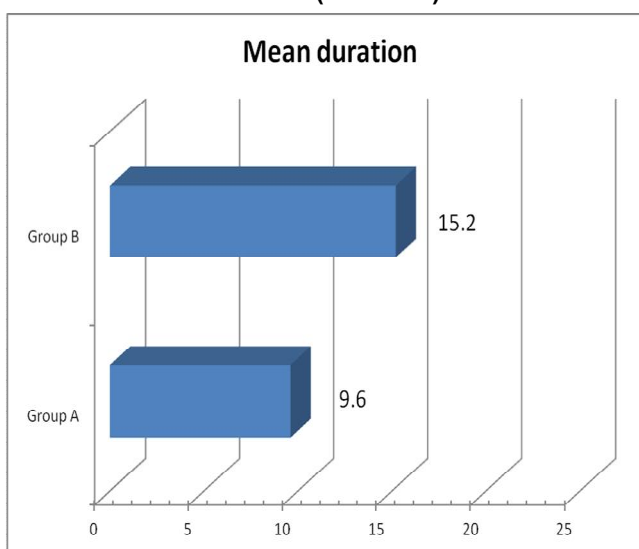


TABLE I: TOTAL NO. OF PATIENTS, GENDER DISTRIBUTION, MEAN AGE AND INVOLVEMENT OF ONE OR TWO EAR IN EACH GROUP A AND B

	Total no. of Patients	Gender distribution		Mean age (years)	Ear involvement	
		Male	Female		One ear	Two ears
Group A	100	61	39	22.9	51	49
Group B	100	52	48	25.7	43	57
Total	200	113	87	24.3	94	106

DISCUSSION

Otomycosis is a superficial fungal infection of the external auditory canal that is frequently encountered by the otorhinolaryngologist. Andrall and Gaverret were the first to describe fungal infection of the ear⁷. The main causative organisms of this condition are aspergillus and candida but it is still controversial whether the fungal species are the true infective agents or mere colonization of fungi as a result of compromised local host immunity due to some bacterial infection or change in normal flora. There are many predisposing factors identified for causation of otomycosis like presence or absence of ear wax, hot and humid climatic conditions, use of instruments in the ear canal, use of systemic or topical antibiotics and steroids, previous mastoid surgeries, immuno-compromised conditions and use of hearing aids⁸.

Otomycosis may present as acute or sometimes as sub-acute variety and is characterized by inflammation of the canal, scaling, itching and sometimes severe discomfort. The fungal debris may collect in the external auditory canal leading to aural fullness and hearing impairment. Itching of the external auditory canal is considered as a hall mark symptom of otomycosis and is reported to be present up to 93% of the cases⁸. Otomycosis sometimes presents as challenging disease because of its high recurrence rate⁹. The treatment recommendation for this condition include topical and rarely systemic antifungal, keeping the ear dry, aural toilet, discontinuation of antibiotic and clearance of the fungal debris. Topical clotrimazole drops or cream is one of the most widely used antifungal agent which is considered as very effective in almost all cases^{10,11}. Clotrimazole is also considered to have some antibacterial effect, thus have an added advantage when treating mixed fungal and bacterial infections¹¹. Other topical antifungal agents are also in use and considered very effective in otomycosis like 3% salicylic acid¹², tincture mertheolate¹³, povidone iodine¹, voriconazole¹⁴, miconazole¹⁵ etc.

Suction cleaning of the external auditory canal is one of the best method to clear the canal with fungal debris. Syringing is another method for removal of debris from the canal, but most workers believe it has to be avoided because some water remains in the canal after syringing and predisposes to more fungal infection. Many patients are very fearful and hesitant to perform suction cleaning on their ear canal. Suction cleaning is sometimes very difficult to perform on the children and young females. Our study shows that although suction cleaning is sometimes very difficult to do but it is a very effective way to clear external auditory canal. It reduces the all over complete resolution time in this condition. So every patient of otomycosis should be counseled about this procedure and it

should be done in every patient.

CONCLUSION

Suction cleaning of the external auditory canal for removal of fungal debris is very helpful and it reduces the time duration for complete resolution. So it should be performed in every patient of otomycosis to remove fungal debris.

ACKNOWLEDGEMENT

We are extremely thankful to the administrative staff of all the three hospital for facilitation they provided us to conduct this study.

CONFLICT OF INTEREST

None.

REFERENCES

1. Ajay Philip, Regi Thomas, Anand Job, V. Rajan-Sundaresan, ShaliniAnandan, and Rita Ruby Albert, "Effectiveness of 7.5 Percent Povidone Iodine in Comparison to 1 Percent Clotrimazole with Lignocaine in the Treatment of Otomycosis," ISRN Otolaryngology, vol. 2013, Article ID 239730, 8 pages, 2013. doi:10.1155/2013/239730
2. Kaur R, Mittal N, Kakkar M, Aggarwal AK, Mathur MD. Otomycosis: a clinicomycologic study. Ear Nose Throat J. 2000;79(8):606-9.
3. Kumar A. Fungal spectrum in otomycosis patients. JK Science, 2005;7(3):152-5.
4. Pradhan B, Tuladhar NR, Amatya RM. Prevalence of otomycosis in outpatient department of Otolaryngology in Tribhuvan University Teaching Hospital, Kathmandu, Nepal. Annals of OtolRhinol-Laryngol., 2003;112(4):384-7.
5. Jackman A, Ward R, April M, Bent J. Topical antibiotic induced otomycosis. Int J Pediatr Otorhinolaryngol., 2005;69(6):857-60.
6. Abou-Halawa AS, Khan MA, Alrobaee AA, Alzolibani AA, Alshobaili HA. Otomycosis with perforated tympanic membrane: self medication with topical antifungal solution versus medicated ear wick. Int J Health Sci (Qassim). 2012;6(1):73-7.
7. Wadhvani K., Srivastava AK. Fungi from otitis media of agricultural field workers. Mycopathologia, 1984;88(2-3):155-9.
8. Anwar K., Gohar MS. Otomycosis; clinical features, predisposing factors and treatment implications. Pak J Med Sci., 2014;30(3):564-7.
9. Ho T, Vrabec JT, Yoo D, Coker NJ. Ho Otomycosis; clinical features and treatment implications. Otolaryngol Head Neck Surg., 2006;135(5):787-91.
10. Khan F, Muhammad R, Khan MR, Rehman F, Iqbal J, Khan M, Ullah G. Efficacy of topical

- clotrimazole in otomycosis. J Ayub Med Coll Abbottabad. 2013 Jan-Jun;25(1-2):78-80.
11. Munguia R., Daniel SJ. Otological antifungals and otomycosis: a review. International J Paediatric Otorhinolaryngol., 2008;72 (4):453-59.
 12. Malik AA., Malik SN., Aslam MA. Comparative efficacy of topical clotrimazole and 3% salicylic acid in otomycosis. Rawal Med J., 2012;37(1):46-9.
 13. Malik FM., Akram S., Zia R. Otomycosis. Professional Med J., 2009; 16(3): 419-23.
 14. Yenisehirli G, Bulut Y, Guven M, Gunday E. In vitro activities of fluconazole, itraconazole and voriconazole against otomycotic fungal pathogens. J Laryngol Otol., 2009; 123(9):978-81.
 15. Kiakojuri K, Roushan MR, Sepidgar SA. Suction clearance and 2% topical miconazole versus the same combination with acidic drops in the treatment of otomycosis. Southeast Asian J Trop Med Public Health., 2007; 38(4):749-53.



AUTHOR AFFILIATION:

Dr. Muhammad Rafique (*Corresponding Author*)

Assistant Professor, Department of ENT
Liaquat University of Medical & Health Sciences
(LUMHS), Jamshoro, Sindh-Pakistan.
Email: rafique.kaimkhani@gmail.com

Dr. Iqbal Hussain Udaipurwala

Bahria University Medical & Dental College
Karachi, Sindh-Pakistan.

Dr. Ehsan - Ul - Haq

Sheikh Zayed Medical College & Hospital
Rahim Yar Khan, Pakistan.

This article may be cited as: Rafique R, Udaipurwala IH, Ehsan-ul-Haq. Suction Cleaning of the External Auditory Canal in Otomycosis: Is it Really Helpful? J Liaquat Uni Med Health Sci. 2014;13(03):97-100.