

## Ultrasound Findings in Adult Patients with Chronic Shoulder Pain Having No History of Trauma

Madiha Imtiaz<sup>1</sup>, Khawaja Muhammad Baqir Hassan<sup>1</sup>, Shakil Sarwar<sup>1</sup>, Ahmed Mushtaq<sup>2</sup>,  
Talat Yasmeen<sup>3</sup>, Sumera Tabassum<sup>4</sup>

<sup>1</sup>Department of Radiology, CMH Malir, Karachi, Sindh-Pakistan.

<sup>2</sup>Department of Surgery, KIMS Malir, Karachi, Sindh-Pakistan.

<sup>3</sup>Department of Anatomy, Liaquat College of Medicine & Dentistry, Karachi, Sindh-Pakistan.

<sup>4</sup>Dr. Sumera Tabassum: Department of Radiology, JPMC Karachi, Sindh-Pakistan.

**Correspondence:** imtiaztalat@gmail.com

doi: 10.22442/jlumhs.2023.01035

### ABSTRACT

**OBJECTIVE:** To evaluate the frequency of non-traumatic chronic shoulder pain sonographically in the local population.

**METHODOLOGY:** This cross-sectional study was conducted at the Department of Radiology, Combined Military Hospital Malir, from March to October 2020. A history of shoulder pain of more than one month duration was included. Patients with a History of shoulder dislocation, neurological, renal, hepatic and cardiac diseases were excluded. The sample size was 196. A non-probability consecutive sampling technique was employed. SPSS version 23 was used for statistical analysis.

**RESULTS:** 196 patients (69.9% males and 30.1% females) with non-traumatic shoulder pain (56.4 % right side and 43.4% left) were scanned. The mean age was 42.80±11.20 years. Out of 196, 118(60.2%) were having complaints in dominant limbs (right 51.0% and left 9.2%); 78(39.8%) were having pain in non-dominant limbs (right 6.6% and left 33.2%). Significant findings were supraspinatus partial tear (46.9%), sub-acromial sub-deltoid bursitis(8.2%), and biceps tenosynovitis(6.1%), adhesive capsulitis, a complete tear of supraspinatus tendon, impingement syndrome, joint effusion, subscapularis tendon tear and tenosynovitis. 44(22.4%) patients had two pathologies, and 31 (15.8%) patients had three pathologies, respectively. Significant co-existent findings were biceps tenosynovitis (13.8%), Impingement syndrome (9.2%), bursitis (8.2%) and joint effusion (7.1%). Age and number of pathological were moderately positively correlated,  $r(194) = 0.46, p < 0.01$  and keeping CI = 95%.

**CONCLUSION:** Partial tears of the supraspinatus tendon were the most common pathology in non-traumatic shoulder myalgia, diagnosed on ultrasound, followed by sub-acromial sub-deltoid bursitis and biceps tenosynovitis, having moderate linear relation with age.

**KEYWORDS:** Shoulder pain, Impingement syndrome, Rotator Cuff Tears, Tenosynovitis, Ultrasound shoulder

**INTRODUCTION**

Shoulder pain is a common problem<sup>1,2</sup>. The most commonly done investigation for it is the shoulder radiograph. Most of the time, it is non-conclusive, especially when there is no history of trauma. Magnetic Resonance Imaging (MRI) has been proven to be very effective and accurate in diagnosing common shoulder pathologies related to ligaments, muscles and bones<sup>3</sup>. MRI is not a cost-effective modality and has limited availability. It is also time consuming and has limitations due to claustrophobia, metallic implants, etc. Ultrasound (US) has been gaining popularity for evaluating musculoskeletal diseases, especially joints<sup>4</sup>. The ultrasound shoulder has been proven equivocal to MRI in many aspects<sup>5</sup>. In addition, the US provides dynamic study, which is impossible in MRI. Furthermore, many interventions can be done under US guidance. The sole limitation of the US is that it is operator dependent. Still, in the experienced hands, it can be an effective diagnostic and prognostic radiological modality as a significant difference may occur in clinical and sonographic findings<sup>6,7</sup>.

Non-traumatic shoulder chronic shoulder pain is a common complaint in routine rehabilitation, geriatrics and orthopaedic outpatient departments (OPD's)<sup>8</sup>. X-ray advised in these patients provides no clinically significant information. Although many criteria for diagnosing rotator cuff syndrome, impingement syndrome and bursitis have been proposed on X-ray, their accuracy and validity are always questionable. A recent comparative study between X-ray shoulders and the US was done in Bangladesh<sup>9</sup>. The study revealed that many X-rays were normal despite having clinical symptoms and positive shoulder ultrasounds<sup>9</sup>. MRI has been proven to be the gold standard in diagnosing musculoskeletal pathologies. However, its limited availability and cost have limited its use. The US shoulder has gained popularity in recent years due to its high sensitivity and specificity for efficiently diagnosing shoulder joint pathologies.

Many international studies have been conducted where the US shoulder has been proven effective in early diagnosis of already described common shoulder pathologies<sup>1,10</sup>. However, no such study has been found in local literature and population.

The rationale of this study was to assess and estimate the frequency distribution of common etiologies of non-traumatic chronic shoulder pain seen in the US; this would help the clinicians decide, treat and follow such patients with better clinical precision and reduce the burden on the MRI departments.

**METHODOLOGY**

This cross-sectional descriptive study was conducted at Combined Military Hospital (CMH) Malir Karachi in March-October 2020. The sample size was calculated by a comparative cross-sectional formula having a precision of 5% with 50% prevalence and a confidence interval of 95%. The sample size was 196 subjects, 137 male and 59 female, with ages ranging from 40 to 70 years.

Inclusion criteria were the subjects with myalgia shoulder of more than one-month duration but no history of trauma. Exclusion Criteria included patients with a history of shoulder instability or dislocation, shoulder diseases such as rotator cuff injury and biceps tendinopathy, rotator cuff surgery, weak shoulder due to neurological problems, brachial plexopathy, diabetes mellitus, rheumatic disorders and systemic diseases like renal, hepatic and cardiac.

All the patients who visited the rehabilitation and orthopedic outpatient departments (OPDs) of CMH Malir for non-traumatic shoulder pain during the period March – October 2020 were included in the study via open invitation.

Informed consent was taken from all the subjects who fulfilled the inclusion criteria. A single radiologist carried out shoulder US; both shoulders were examined on My Lab7, eSaote ultrasound Machine with 8-15 MHz linear array probe. US was carried out under the guidelines of the European Society of Musculoskeletal Radiology and the European Society of Radiology (ESOR) <sup>11,12</sup>.

The joints were examined for the pathologies like supraspinatus (SS) partial or complete tears, biceps tenosynovitis, sub-acromial sub-deltoid (SASD) bursitis, joint effusion, impingement Syndrome, degenerative changes, adhesive capsulitis, subscapularis (SUBS) partial tear and subscapularis tenosynovitis. For the study of Supraspinatus tendon patient was seated on a stool, 90 degrees to the examiner, to the side of shoulder to be studied with hand on back pocket and elbow tucked in, probe in coronal position giving long axis view. The patient's position remained the same for the short-axis study, but the probe was placed in a sagittal position<sup>11</sup>.

For the long head of the biceps patient seated with the arm on the side, elbow flexed, palm facing upwards, a probe was placed on the anterior part of the deltoid axial to the upper arm; it showed a transverse view of the tendon.

The subscapularis tendon patient was seated with the arm on the side and externally rotated, elbow flexed, palm facing upwards; a probe was placed on the anterior part of the deltoid, axial to the upper arm and dominant shoulder and joint pathologies were diagnosed on the US.

Data was collected and recorded on a proforma, including age, gender and ethnicity.

Means and age ranges were calculated, and pathogen frequencies were also recorded. Data was then statistically analyzed with SPSS ver. 23.0 (SPSS Inc., Chicago, IL, USA) for Windows 10.0. The study was carried out after approval from the Ethical Committee (CMH Malir letter Ref: 19/2020/Trg/Adm).

**RESULTS**

A total of 196 patients with non-traumatic shoulder pain were scanned; out of these, 137(69.9%) were males and 59(30.1%) were females. The mean age was  $42.80 \pm 11.20$  years (range 18-75 years). It was observed that the right shoulder was involved more than the left one, with 111(56.4%) patients having pathologies in the right shoulder and 85(43.4%) in the left one.

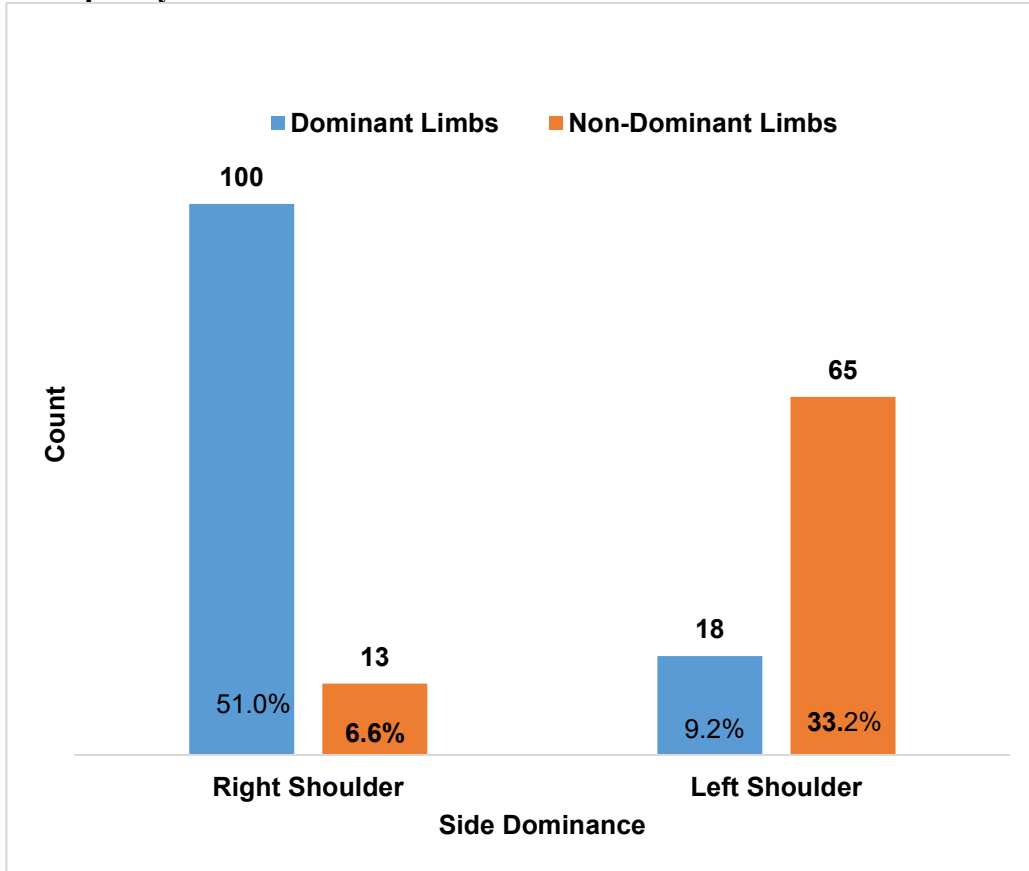
Out of 196 patients, 118(60.2%) had complaints in the dominant limbs; 100(51.0%) were in the right dominant, and 18(9.2%) had pain in the left dominant. Seventy-eight patients (39.8%) had complaints in non-dominant shoulders, 13 in the right (6.6%) and 65 in the left (33.2%), as shown in **Figure I**.

The significant findings observed were the supraspinatus tendon's focal hypoechoic defect (partial tear). Of 196 patients, 92 (46.9%) had this pathology (**Figure II**). In 57 patients (29.1%), the scan was normal; second in frequency was sub-acromial sub-deltoid bursitis (8.2%); anechoic fluid collection with thickening of synovial covering was noted in this condition. There was fluid around the tendon, i.e., Biceps tenosynovitis present in (6.1%) of patients; there was a lack of visualization of supraspinatus tendon or concave superficial surface in (3.6%), indicating partial tear. **Table I** shows adhesive capsulitis, impingement syndrome, joint effusion, subscapularis tendon tear, and tenosynovitis were the next frequent pathologies.

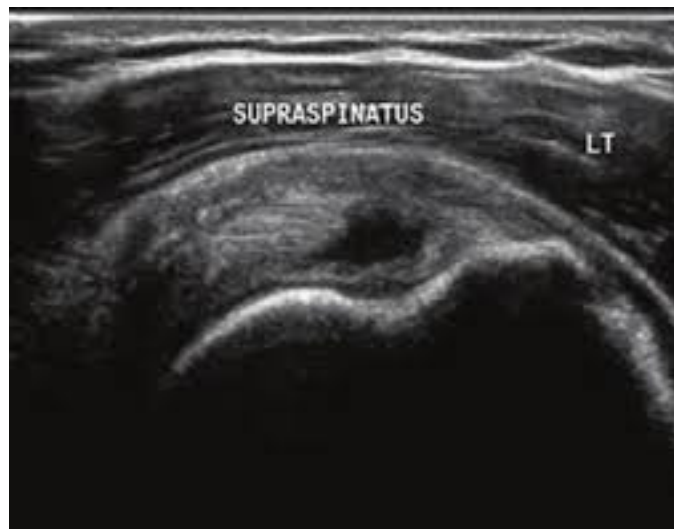
**Table II** shows the frequency distribution of the pathologies in a single patient. Fifty-seven patients (29.1%) had pain, but the US shoulder was normal. 64 (32.7%) patients had single abnormality, 44(22.4%) had two and 31(15.8%) had three pathologies respectively.

Significant co-existent findings were biceps tenosynovitis (13.8%), Impingement syndrome (9.2%), sub-acromial sub-deltoid bursitis (8.2%) and Joint effusion (7.1%).

**Figure I: Frequency of Shoulder Pain vis-à-vis Dominance of Limbs**



**Figure II: Supraspinatus Partial Tear**



**Table I: Frequencies of Major Findings**

	<b>Frequency</b>	<b>Percentage</b>
Supraspinatus partial tear	92	46.9
Normal	57	29.1
Sub-acromial sub-deltoid bursitis	16	8.2
Biceps tenosynovitis	12	6.1
SS complete tear	7	3.6
Adhesive capsulitis	5	2.6
Joint Effusion	2	1
Impingement Syndrome	2	1
Degenerative changes	1	0.5
SUBS partial tear	1	0.5
Tenosynovitis SUBS	1	0.5
<b>Total</b>	<b>196</b>	<b>100</b>

**Table II: Number of Findings in a Patient**

		<b>Frequency</b>	<b>Percent</b>
Valid	0	57	29.1
	1	64	32.7
	2	44	22.4
	3	31	15.8
	<b>Total</b>	<b>196</b>	<b>100.0</b>

## DISCUSSION

Rotator-cuff pathologies are the most frequent findings in patients with shoulder pain. The X-ray usually provides no diagnostic clue that can lead to a specific diagnosis. Various comparative studies have revealed that X-rays have a limited role in non-traumatic shoulder pain when compared to other imaging modalities such as ultrasound, Computed tomography (CT) and MRI<sup>9,13-16</sup>. US shoulder has proven to have better diagnostic accuracy than plain X-ray, especially in non-traumatic conditions<sup>13</sup>. Cross-sectional imaging CT and MRI have both limited availability as well as issues of cost. Therefore, the following effective imaging modality is the US shoulder.

Various international studies have shown the efficacy of shoulder US in detecting soft tissue abnormalities in chronic non-traumatic shoulder pains<sup>4,10,14,17,18</sup>. In addition to this, they are equally crucial in treating the sequels or accompanied ligamentous injuries in traumatic shoulders as well<sup>19,20</sup>.

The present study is also comparable to the findings of Singh AP 2017<sup>15</sup>, who reported the frequency of rotator cuff pathologies is more common in man (50% male and 44% female); we have also noticed that in our population, man outnumbered women (69% and 30.1% respectively).

This cross-sectional study reported the incidence of shoulder pathologies to be 69.9% in patients with painful shoulders without any history of trauma. In a study carried out by Lagnocco A 2003<sup>21</sup>, recording shoulder pathologies, an overall incidence reported was 0.9-2.5%; this figure is in contrast to that in our population.

The results of our study are comparable to the studies done in the past. In the study carried out by Lagnocco A 2003<sup>21</sup> and Naredo E et al.<sup>22</sup>, the supraspinatus tendon was the commonest tendon involved; our study is also in agreement with it, but the frequencies of other pathologies of the study were different from that of our analysis.

The significant finding in our study was a partial tear of the SS tendon (46.9%). No significant correlation was found between the partial tear and limb dominance. The second most common pathology was sub-acromial sub-deltoid bursitis (8.2%), followed by biceps tenosynovitis (6.1%); these findings conform with Jiang L et al.<sup>23</sup>. On the other hand, our results are contrary to Ottenheijm RP et al.<sup>24</sup>, who noticed that calcific tendonitis was the most frequently diagnosed disorder (29%) and the second most common abnormality in his study was sub-acromial sub-deltoid bursitis (12%). Tenosynovitis of the proximal portion of the long head of the biceps (11%) was the third most common in frequency in a local population in the Netherlands; these differences may be attributed to the environmental factors.

The impingement syndrome was reported as the most common finding (93.3%) by Khan MSZ 2019<sup>7</sup>, which is also in contrast to our study; we found only a 1% incidence of this pathology in our population. Furthermore, he found that 46.67% of the patients have a single pathology, while in our population, we found 32.7% of the study subjects having only one pathology. The frequency of a single pathology is also very high in the study of Zheng F et al.<sup>18</sup>, which noticed 82% of the patients had at least one particular cause of rotator cuff syndrome. The reason for these differences could be attributed to race.

The results of several studies by experienced radiologists show the accuracy of ultrasound to be 0.83 and 0.93 for total thickness and partial tear of supraspinatus tendon, respectively<sup>25</sup>. At the same time, Saraya S 2016<sup>16</sup> has described it as 0.90 and 0.83, respectively. These studies also support the result of our study as regards the accuracy of this modality for the diagnosis of pathologies in non-traumatic shoulder pain patients.

## ONLINE FIRST

It is worth mentioning that all these patients have normal shoulder X-rays. This study signifies the value of the US in the evaluation of chronic shoulder pain, especially with no prior history of trauma. We believe the US should be the first line of investigation in such scenarios; this will benefit the patients and physicians and avoid unnecessary radiation exposure. It is the tool of choice if a well-trained radiologist and high-resolution equipment are available.

## CONCLUSION

US shoulder revealed partial supraspinatus tendon tears as the most typical pathology in non-traumatic shoulder pain, followed by sub-acromial sub-deltoid bursitis and biceps tenosynovitis. We have also concluded that ultrasound is a less expensive, reliable and readily available tool when the rotator cuff integrity is the primary concern. These pathologies have a moderate linear positive correlation with the advancing age.

**Limitations & strength of study:** It is a single centre study. The multicenter studies with a large sample size and including all the provinces of Pakistan would have been better, but due to time limitations and cost, it is limited. This study carried out on ultrasound findings, so it may help the doctors to advise this simple procedure for painful shoulders, saving the money and time of the patients and their relatives.

**Acknowledgement:** We acknowledge the cooperation of all the supporting staff of the Department of Radiology, CMH, Malir, Karachi.

**Ethical permission:** Combined Military Hospital, Malir, Karachi, ERC letter No. 19/2020/Trg/Adm.

**Conflict of interest:** The authors declare no conflict of interest.

**Funding:** This research did not receive specific funding from any financially supporting body.

**Data Sharing Statement:** The corresponding author can provide the data proving the findings of this study on request. Privacy or ethical restrictions bound us from sharing the data publically.

## AUTHOR'S CONTRIBUTION

Imtiaz M: Executed the investigation, Prepared the draft, Reviewed the manuscript

Hassan KMB: Conceived & supervised the project, Reviewed the manuscript

Sarwar S: Provided administrative and technical support, Reviewed the manuscript

Mushtaq A: Executed the investigation, provided administrative and technical support, Reviewed the manuscript

Yasmeen T: Reviewed the manuscript

Tabassum S: Reviewed the manuscript



**REFERENCES**

1. Djade CD, Porgo TV, Zomahoun HTV, Perrault-Sullivan G, Dionne CE. Incidence of shoulder pain in 40 years old and over and associated factors: A systematic review. *Eur J Pain*. 2020; 24(1): 39-50. doi: 10.1002/ejp.1482. Epub 2019 Oct 13.
2. Brox JI, Sunde P, Schroder C, Engebretsen K, Skare O, Ekeberg OM. Non-traumatic shoulder pain. *Tidsskrift Nor Praktisk Medicin, NY Raekke*. 2010; 130(21): 2132-5. doi: 10.4045/tidsskr.09.1083.
3. Naqvi GA, Jadaan M, Harrington P. Accuracy of ultrasonography and magnetic resonance imaging for detection of full-thickness rotator cuff tears. *Int J Shoulder Surg*. 2009; 3(4): 94-7. doi: 10.4103/0973-6042.63218.
4. Okoroha KR, Fidai MS, Tramer JS, Davis KD, Kolowich PA. Diagnostic accuracy of ultrasound for rotator cuff tears. *Ultrasonography*. 2019; 38(3): 215-220. doi: 10.14366/usg.18058.
5. Janeiro J, Barreira SC, Martins P, Ninitas P, Campos J, Fonseca JE. Ultrasound Features Associated With Shoulder Complaints: Calcifications Larger Than 6 mm in Young Patients and Positive Doppler Are Associated With Pain. *Front Med(Lausanne)*. 2021; 8: 715423. doi: 10.3389/fmed.2021.715423.
6. Mahajan A, Tobase P, Phelps A, Phelan D, Lesh MB, Giermasz A. Radiologist-performed musculoskeletal ultrasound (MSKUS) for evaluation of joint and soft tissue pain episodes in patients with bleeding disorders. *Blood*. 2015; 126(23): 3266. doi: 10.1182/blood.V126.23.3266.3266.
7. Khan MSZ, Rahman N, Ferdousi MA, Khatoon R, Taher MA. Ultrasonographic findings in patients with shoulder pain. *BIRDEM Med J*. 2019; 9(3): 218-222. doi: 10.3329/BIRDEM.V9I3.43085
8. Lewis J. Rotator Cuff-related shoulder pain. *Advances in understanding and management. J Sci Med Sport*. 2017; 20: 47.
9. Salek KM, Mannan M, Chowdhury AZ, Haque MA, Kaiser MS, Nabi S et al. Comparison between ultrasound and plain X-ray in evaluating the cause of shoulder pain. *Mymensingh Med J*. 2011; 20(1): 16-21.
10. Sconfienza LM, Albano D, Allen G, bazzocchi A, Bignotti B, Cianca V et al. Clinical indications for musculoskeletal ultrasound updated in 2017 by European Society of Musculoskeletal Radiology (ESSR) consensus. *Eur Radiol*. 2018; 28(12): 5338-5351. doi: 10.1007/s00330-018-5474-3. Epub 2018 Jun 6.
11. Martinoli C. Musculoskeletal ultrasound: technical guidelines. *Insights Imaging*. 2010; 1(3): 99-141. doi: 10.1007/s13244-010-0032-9.
12. Tamborrini G, Bianchi S. Ultrasound of the Shoulder (Adapted According to SGUM Guidelines). *Praxis[Bern 1994]*. 2020; 109(7): 521-530. doi: 10.1024/1661-8157/a003470.
13. Mohtasib RS, Alzahrani AM, Asiri YN, Rayes ZF, Alshaalan MA. Accuracy of shoulder ultrasound examination for diagnosis of rotator cuff pathologies: a single-centre retrospective study. *Ann Saudi Med*. 2019; 39(3): 162-171. doi: 10.5144/0256-4947.2019.162.
14. Gupta P, Uppal S, Achuthan K, Adya C, Singh A, Saini J. Sonography: a valuable modality in evaluation of chronic non-traumatic disorders of the shoulder joint. *Med J Armed Forces India*. 1998; 54(1): 27-31. doi: 10.1016/S0377-1237(17)30402-1. Epub 2017 Jun 26.

## ONLINE FIRST

15. Singh AP, Rao A, Devaru S, Amithavikrama. Role of Ultrasound in Evaluation of Shoulder Injuries: A Comparative Study of Ultrasound and MRI. *Int J Anatomy Radiol surgery*. 2017; 6(1): R012-R018. doi: 10.7860/IJARS/2017/24542:2224.
16. Saraya S, El Bakry R. Ultrasound: can it replace MRI in the evaluation of the rotator cuff tears? *Egypt J Radiol Nuclear Med*. 2016; 47(1): 193-201.
17. Papatheodorou A, Ellinas P, Takis F, Tsanis A, Maris I, Batakis N. US of the shoulder: rotator cuff and non-rotator cuff disorders. *Radiographics*. 2006; 26(1): e23. doi: 10.1148/rg.e23.
18. Zheng F, Wang H, Gong H, Fan H, Zhang K, Du L. Role of ultrasound in the detection of rotator-cuff syndrome: an observational study. *Med Sci Monit*. 2019; 25: 5856. doi: 10.12659/MSM.915547.
19. Sconfienza LM, Adriaensen M, Albano D, allen G, Gomez MP, Bazzocchi A et al. Clinical indications for image-guided interventional procedures in the musculoskeletal system: a Delphi-based consensus paper from the European Society of Musculoskeletal Radiology (ESSR)—part I, shoulder. *Eur Radiol*. 2020; 30(2): 903-913. doi: 10.1007/s00330-019-06419-x. Epub 2019 Sep 16.
20. Chang K-V, Mezian K, Naňka O, Wu W-T, Lin C-P, Özçakar L. Ultrasound-guided interventions for painful shoulder: from anatomy to evidence. *J Pain Res*. 2018; 11: 2311-2322. doi: 10.2147/JPR.S169434.
21. Lagnocco A, Coari G, Leone A, Valesini G. Sonographic study of painful shoulder. *Clin Exp Rheumatol*. 2003; 21(3): 355-8.
22. Naredo E, Aguado P, De Miguel E, Usan J, Mayordomo L, Gijon-Banos J et al. Painful shoulder: comparison of physical examination and ultrasonographic findings. *Ann Rheumatic Dis*. 2002; 61(2): 132-136. doi: 10.1136/ard.61.2.132.
23. Jiang L, He J, Chen CP, Xie D, Mai Y, Yue B et al. The Ultrasonographic Features of Shoulder Pain Patients in a Tertiary Hospital in South China. *Biomed Res Int*. 2020; 2020: 3024793. doi: 10.1155/2020/3024793.
24. Ottenheijm RP, van't Klooster IG, Starmans LM, Vanderdood K, de Bie RA, Dinant G et al. Ultrasound-diagnosed disorders in shoulder patients in daily general practice: a retrospective observational study. *BMC Fam Pract*. 2014; 15: 115. doi: 10.1186/1471-2296-15-115.
25. Farooqi AS, Lee A, Novikov D, Kelly AM, Li X, Kelly 4<sup>th</sup> JD et al. Diagnostic accuracy of ultrasonography for rotator cuff tears: a systematic review and meta-analysis. *Orthop J Sports Med*. 2021; 9(10): 23259671211035106. doi: 10.1177/23259671211035106.