

## **Dacryo Cysto Rhinostomy with Intubation: Anterior Flap Versus Flap Excision. A Comparative Study**

Mariya Nazish Memon, Sajida Parveen Sheikh, Waheed Ahmed Sheikh, Farah Naz Memon, Ashok Kumar Narsani

1. **Dr. Mariya Nazish Memon**, FCPS(Ophth), FCPS (Peads Ophth)  
Institute of Ophthalmology.  
Liaquat University of Medical and Health Sciences. Jamshoro.
2. **Dr. Sajida Parveen Sheikh**, FCPS.  
Department of ophthalmology.  
Bilawal Medical College. Jamshoro.
3. **Dr. Waheed Ahmed Sheikh**, FCPS.  
Senior Medical Officer,  
Dr. Routh KM PFAU Civil Hospital Karachi.
4. **Dr. Farah Naz Memon**. MSPH  
Epidemiologist. Pakistan Health Research Council (Head Office). Islamabad.
5. **Dr. Ashok Kumar Narsani**, FCPS  
Director & Professor, Institute of Ophthalmology  
Liaquat University of Medical and Health Sciences. Jamshoro.

### **Correspondence:**

Dr. Mariya Nazish Memon, FCPS (Ophth), FCPS (Peads Ophth), FICO  
Associate Professor  
Institute of Ophthalmology,  
Liaquat University of Medical and Health Sciences. Jamshoro.  
E-mail: [mariyamemon@hotmail.com](mailto:mariyamemon@hotmail.com)  
Cell: 92-3002668558

**ABSTRACT**

**OBJECTIVE:** To assess the efficacy of dacryocystorhinostomy with intubation, with and without anterior flap suturing in patients with chronic dacryocystitis secondary to the nasolacrimal duct obstruction.

**METHODOLOGY:** Comparative cross-sectional study was carried out at Institute of Ophthalmology, Liaquat University of Medical & Health Sciences Jamshoro. All the patients underwent external dacryocystorhinostomy during July 2016 to June 2019 were included by convenient sampling technique. Patients data were allocated into two groups. Group A (Anterior flap anastomosis) and group B (flap excision). Success rate of surgery was assessed at 3 months and 6 months follow up visits.

Data were analysed by SPSS 23, frequencies and percentages for categorical variables and mean and averages for numerical variables were calculated,  $\chi^2$  (chi-square) applied on surgical outcome comparing two techniques. P-value  $< 0.05$  was considered as significant.

**RESULTS:** Fifty-seven patients (57 eyes) were included in this study. Thirty-four eyes in Group A (anterior flap suturing) and 23 eyes in Group B (flap excision). Mean age of the patient in Group A was 42.50 years $\pm$ 11.88 and in Group B was 42.10 years $\pm$ 16.78 (P=0.923). Most of the operated patients were females such as 55.9% and 69.6% in Group A and B respectively (P=0.298).

The overall success outcome of DCR with silicon tube intubation was 93%. Thirty-one eyes (91.2%) in Group A and 22 eyes (95.7%) in Group B were labelled as successful (P=0.641).

**CONCLUSION:** Excision of mucosal flap is effective and comparatively easier. It shortens the procedure time and decrease hazards of general anaesthesia.

**KEY WORDS:** Chronic Dacryocystitis, dacryocystorhinostomy, Epiphora, Flap anastomosis, Flap excision.

**INTRODUCTION**

Constant epiphora is the commonest symptom of Chronic dacryocystitis secondary to nasolacrimal duct (NLD) obstruction<sup>1</sup>. It is bothersome symptom which affects the patients social and functional life. The condition is mostly unilateral but both eyes can be involved. Prolong tears stasis in lacrimal sac invites secondary bacterial infection which can lead to acute on chronic dacryocystitis.

Dacryocystorhinostomy (DCR) was introduced by a French ophthalmologist Adeo Toti, in 1904 for the treatment of chronic dacryocystitis<sup>2</sup>. In 1920-1921, Dupuy-Dutemps and Bourguet suggested for epithelial lined fistula by anastomosing lacrimal and nasal mucosa<sup>3</sup>. DCR creates the low resistant newly formed fistula by making osteotomy in nasal bone and anastomosis between lacrimal sac and lateral nasal mucosa. This fistula bypasses the obstruction at the level of NLD which normally opens under the inferior turbinate and drain tears directly into nasal cavity under the middle meatus from the lacrimal sac.

The available treatment modalities for constant watery eye resulting from obstruction of the nasolacrimal ducts are conventional external approach DCR(EX-DCR) with or without mitomycin C, internal approach endoscopic/endo nasal DCR (ENDO-DCR)<sup>4</sup>, endocanalicular laser DCR, Endoscopic balloon assisted DCR and balloon dacryoplasty. Endo DCR has the advantage of suture less surgery, short recovery time and less morbidity but on the other hand procedure has steep learning curve, need costly instruments and trained surgical team<sup>5-6</sup>.

External DCR is more popular, successful and widely accepted treatment modality for chronic dacryocystitis especially in underprivileged areas<sup>7</sup>. According to literature, various modifications in the surgical steps such as size of flap, single flap technique, double flap technique and flap excision has been carried out to achieve better surgical outcome without disturbing its native concept<sup>8-11</sup>, limited data is available to assess the success rate of DCR with anterior flap suturing in comparison to DCR with total flap excision.

The purpose of this study was to assess the efficacy of dacryocystorhinostomy with intubation, with and without anterior flap suturing in patients with chronic dacryocystitis secondary to the nasolacrimal duct obstruction.

**METHODOLOGY**

Comparative cross-sectional study was carried out on secondary data from medical records. Due to less numbers of patients, Judgmental sampling technique (Extension of convenient sampling) was used to get study sample. Therefore, all the patients who presented with dacryocystitis underwent external dacryocystorhinostomy during July 2016 to June 2019 at Institute of Ophthalmology, Liaquat University of Medical & Health Sciences Jamshoro were identified and included in the study.

Patients with constant epiphora due to NLD obstruction (confirmed by syringing of lacrimal passage and ruled out any nasal pathology by otorhinolaryngologist), regurgitation test positive and diagnosed as chronic dacryocystitis were included without discrimination of age and sex. Patients with any nasal abnormalities such as nasal polyps, hypertrophied inferior turbinate, deviated nasal septum, tumours and previous failed DCR were excluded from the study. Patient's data including demographic details, surgical techniques, surgical outcome or success rate and follow up period were retrieved from patient chart from the hospital record.

In this way using judgmental sampling technique total sample size turned out was 57 patients (Study participants). Further, study participants were divided into two groups A and B depending upon the surgical techniques used. Group A included eye in which suturing of only anterior flap was done and Group B included eyes in which no flap was created and both anterior and posterior flap were excised. All surgeries were performed under hypotensive general anaesthesia and standard surgical steps of external DCR were performed. Before starting surgery, nasal cavity was packed with 2% lidocaine and 1: 200,000 epinephrine. After vertical skin incision and blunt muscle dissection, Periosteum was reflected off the lacrimal bone with the help of Periosteum elevator and opening was made in lacrimal bone by using a Kerrison bone punch. A vertical incision was given in nasal mucosa and lacrimal sac wall and flaps were made. DCR tube was inserted in all the patients and tied into the nasal cavity. In Group A posterior flap were excised and anterior flap of nasal mucosa and lacrimal sac was sutured with 6/0 vicryl suture. In Group B, anterior as well as posterior flap were excised and no flap was created. Muscle and skin were sutured layer by layer with 6/0 vicryl suture.

Post operatively nasal packing was left for one day. Post operatively all patient prescribed capsule ciprofloxacin 500 mg BID for 05 days and tablet Ibuprofen 400 mg twice a day for 03 days. Patient who had heavy bleeding intraoperatively were kept on capsule tranexamic acid 500 mg BID for 03 days. Patient were advised to take rest for one week and avoid heavy weight lifting and nose blowing to prevent secondary nasal bleeding. On first post-operative day moxifloxacin 0.5% with Dexamethasone 0.1% eye drops four times a day for one week and neomycin, polymyxin B and bacitracin ointment (Polyfax) for skin wound for 10 days were prescribed.

Follow up advised at 1 week, 1 month, 3 months and 6 months. Silicon tube was removed 3 to 6 months after surgery. After removal of the tube all patient underwent syringing of lacrimal passage with gentamycin splash under topical anaesthesia to confirm the patency of DCR fistula. Success rate of surgery was assessed at 3 months and 6 months follow up visits by subjective method (reduction or absence of symptoms of epiphora) as well as objective method (patent lacrimal fistula on syringing of lacrimal drainage system). Patient with persistent epiphora and / or failure to irrigate lacrimal fistula on syringing were labelled as surgical failure.

Data were analysed by SPSS 23, frequencies and percentages for categorical variables and mean and averages for numerical variables were calculated. Student t test applied for age and follow up period and  $\chi^2$  (chi-square) applied for gender and surgical outcome comparing two techniques. P-value  $< 0.05$  was considered as significant.

**RESULTS**

According to research protocol, medical record of 57 eyes of 57 patients were identified and included in this study. In Thirty-four eyes, only anterior flap suturing (Group A) was done and in 23 eyes, anterior and posterior flap excised and flap less DCR was performed (Group B). Mean age of the patient in Group A was 42.50 years±11.88 and in Group B was 42.10 years±16.79 (P=0.923). Most of the operated patients were females such as 56% in Group A and 69.6% in Group B(P=0.298). There was no statistical difference when compared in terms of age and gender between two groups (Table I).

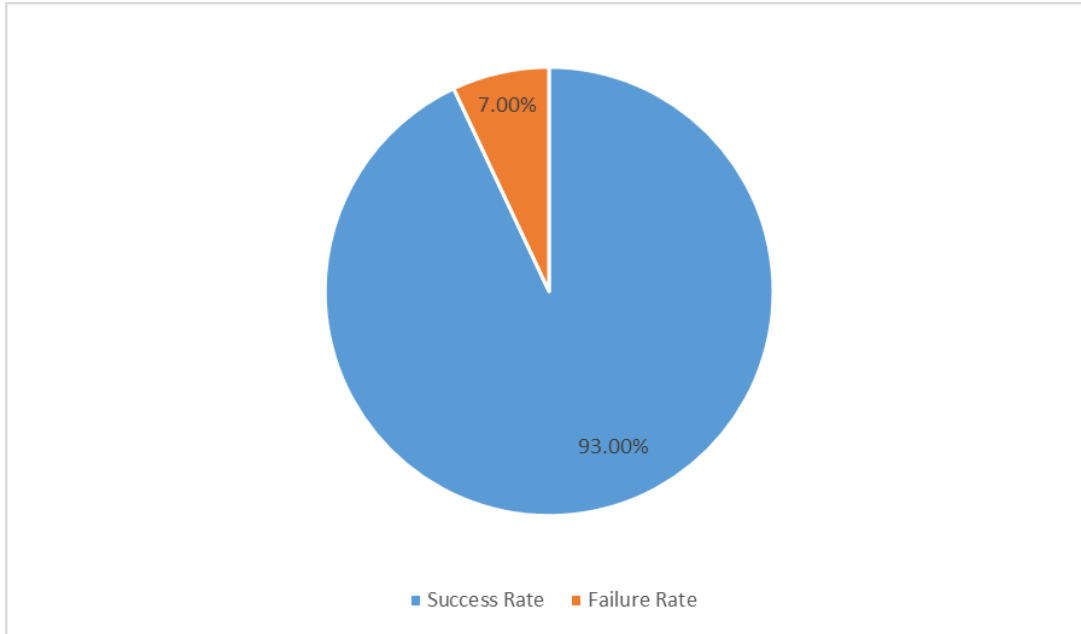
The overall success outcome of DCR with intubation in our study was 93%. (Figure I). Thirty-one eyes (91.2%) in Group A and 22 eyes (95.7%) in Group B were labelled as successful on the basis of absence or reduction of epiphora and patent lacrimal passage on syringing (Figure II) whereas 3 eyes (8.8%) in Group A and 1 eye (4.3%) in Group B were in failure and advised Re DCR surgery. Comparison of surgical outcome between two groups was statistical insignificance (P=0.641). Flapless DCR does not adversely affect the outcome of surgery.

**TABLE I: COMPARISON OF TYPE OF SURGERY WITH GENDER, AGE & SUCCESS RATE (n = 57)**

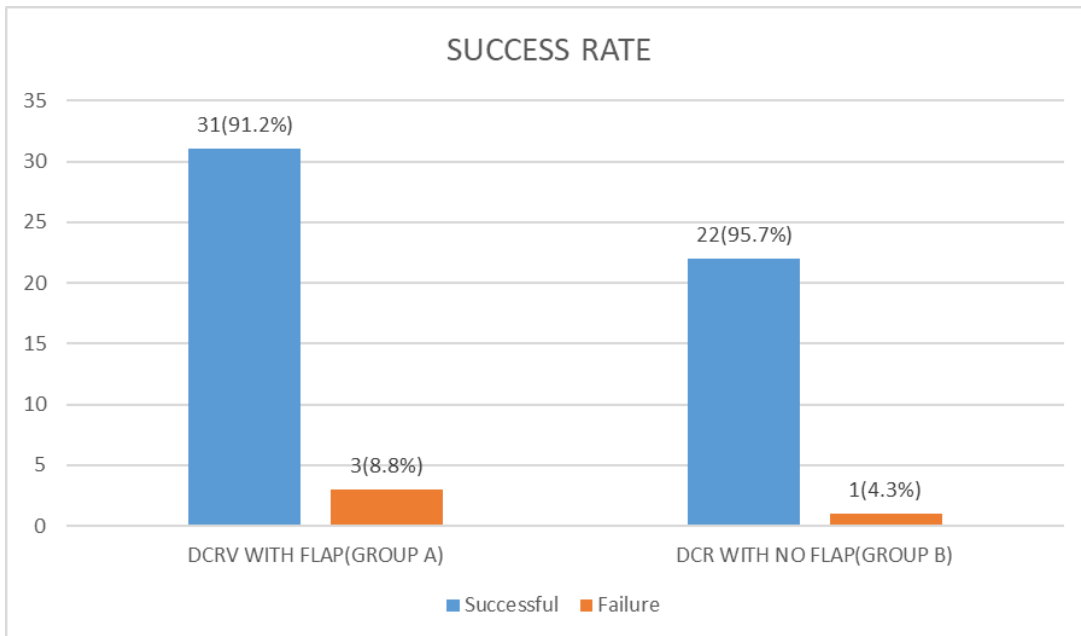
|   | DCR WITH FLAP                   | DCR WITHOUT FLAP                 | P – Value |
|---|---------------------------------|----------------------------------|-----------|
| No: of patients                                 | 34                              | 23                               | --        |
| <b>AGE</b><br>(Mean+/_ SD)<br>Range             | 42.50yrs±11.88<br>20yrs – 70yrs | 42.10 yrs±16.79<br>20yrs – 73yrs | 0.923*    |
| <b>SEX</b><br>MALE                              | 15 (44.1%)                      | 7 (30.4%)                        | 0.298**   |
| FEMALE  | 19 (55.9 %)                     | 16 (69.6%)                       |           |
| <b>FOLLOW UP</b><br>(Mean + /_ SD)<br>In months | 6.0± 2.0                        | 5.0 ±2.0                         | 0.391*    |
| <b>SURGICAL OUTCOME</b><br>Success<br>Failure   | 31 (91.2%)<br>3 (8.8 %)         | 22 (95.7 %)<br>1 (4.3 %)         | 0.641**   |

\*Student t test, \*\*chi square test

**FIGURE I: OVERALL SUCCESS RATE OF EXTERNAL DCR WITH SILICONE TUBE**



**FIGURE II: COMPARISON OF SUCCESS RATE OF BOTH GROUPS**



## DISCUSSION

External dacryocystorhinostomy with silicon tube intubation remains the Gold Standard and most successful surgical procedure for Nasolacrimal duct obstruction and commonly performed in oculoplasty and general ophthalmology over several decades.

In our study total number of 57 eyes of 57 patients were included, majority of patient were in the age range of between 20 – 73 years. The mean age of the patient in Group A was  $42.50 \pm 11.88$  and in Group B was  $42.12 \text{ years} \pm 16.79$  (Table I). Several studies supported our data in terms of commonest age group<sup>12-13</sup>. Saiju et al<sup>12</sup> mentioned mean age of 41 years with age range between 18 - 82 years. Another study by Zaman et al<sup>13</sup> stated that majority of the patient were in the age range of 40-60 years. However, Baldeschi et al<sup>14</sup> studied patient with the age range of 34 – 79 years. Mean age was 62 years, could be due to the reason that they have included patients older than 34 years of age.

In present study females was predominantly affected than the males such as 19 patients (55.9%) in Group A and 16 eyes (69.6%) in Group B were females (Table I). Many studies in the literature<sup>7-16</sup> supported the same that NLD obstruction is more commonly seen in middle age and elderly females and more than 60% of the treated patient were females. It could be owing to hormonal changes in middle age female. Narrow lacrimal fossa and middle nasolacrimal duct is also one of the contributing factors in females as well<sup>17</sup>.

The overall success outcome of DCR in this study is 93% (Figure I). In literature, the reported surgical success is 80% to 95% and usually it is better than 90%<sup>18-20</sup>. This high success rate is mainly because of intubation of silicon tube in all the patients. Hussain et al<sup>21</sup> conducted a study and observed high success rate of 94.7% in intubated patients as compared to 71.8% in non-intubated patients. Another study by Advani et al<sup>22</sup> also showed 95% success rate in intubated cases as compared to 88% in non-intubated patients. On other hand some researchers suggest that diameter of Silicon intubation tube is small and incapable to avoid stenosis and actually increase the chances of failure by inducing granulation tissue formation<sup>23</sup>.

Although DCR is standard procedure for nasolacrimal duct obstruction, it has few limitations such as difficult to design and suture mucosal flap due to deep location, limited view because of bleeding in few patients and prolong surgery time under general anaesthesia, so it is challenging as well as time consuming.

In the present study we assess the success outcome of DCR with only anterior flap formation (Group A) and compare with DCR with total flap excision (Group B). The success outcome in Group A was 91.2% and in Group B was 95.7% (Figure II). The results were statistically insignificant (P=0.641) and indicated that both the techniques are equally effective and successful. Takahashi et al<sup>9</sup> conducted a comparative study which supports our data. They included 205 eyes of 178 patients, 57 eyes in double flap anastomosis and 148 eyes in complete flap excision. Comparison of the surgical outcome revealed that DCR without flap had similar surgical outcome (93.2%) as DCR with double flap (93%). Another researcher<sup>24</sup> performed retrospective study including 28 eyes with external DCR with anterior and posterior flap excision and observed 92.8% success rate. They concluded that flapless DCR is effective procedure and flap making does not affect the outcome of surgery. Similarly, Ravi et al<sup>25</sup> retrospectively reviewed the success rate of flapless external DCR with MMC syringing on 5<sup>th</sup> post-operative day and observed success rate of as high as 98.67% at the end of 1 year follow up period.

We believe that excision of flap is easier, simple procedure and shortens the surgery time rather than poorly created and sutured mucosal flap which may block the bony osteum due to fibrosis and granulation tissue. It is also beneficial in those circumstances where patient bleed heavily during surgery and visibility of nasal mucosa is compromised.

## **ONLINE FIRST**

This study has few limitations. It is retrospective study with limited sample size and follow ups. However, larger scale studies including Randomized control trials (RCTs) are recommended for further evidence.

### **CONCLUSION**

Excision of mucosal flaps is effective and comparatively easier. It shortens the procedure time and decrease hazards of general anaesthesia.

**Ethical permission:** Liaquat University of Medical & Health Sciences, Institute of Ophthalmology ERC letter No. 27333/42, dated 23-09-2019.

**Conflict of interest:** There is no conflict of interest in authors.

**Funding:** There was no funding from any agency or institution.

### **AUTHOR CONTRIBUTIONS**

Memon MN: conceived, designed & writing of manuscript

Shaikh S: Data collection, editing

Shaikh W: Editing, final approval

Memon FN: Statistical analysis, final approval

Narsani AK: Editing, final approval



**REFERENCES**

1. Rather S, Singh T. Dacryocystorhinostomy with & without silicon tube intubation in chronic dacryocystitis with nasolacrimal duct block. *K K SCIENCE*. 2013; 15(1): 75-79.
2. Toti A. Nuovo metodo conservatore di cura radicale delle suppurazioni croniche Del Sacco lacrimale (dacriocistorinostomia). *Clin Moderna Firenze*. 1904; 10: 385-9.
3. Alexander JEF. *Essential Ophthalmic Surgery*. First edition. Oxford, UK:Butter-Heinmann; 2001.p.165.
4. Rahman MZ, Hossain MJ. Comparative study of success of Dacryocystorhinostomy with and without silicon tube Intubation. *JAFMC Bangladesh*. 2012; 8(2): 35-38.
5. Arash J, Amadi MD: Endoscopic DCR vs External DCR: What's Best in the Acute Setting. Department of Ophthalmology, Division of Oculoplastic Surgery, University of Washington, Seattle, WA, USA; *J Ophthalmic Vis Res* 2017; 12(3): 251-3.
6. Jain S, Ganguly A, Singh S, Mohapatra S, Tripathy D, Rath S. Primary non endoscopic endonasal versus delayed external dacryocystorhinostomy in acute dacryocystitis. *Ophthal Plast Reconstr Surg* 2016.
7. Long LV, Safinaz MK, Nazila BAA. External dacryocystorhinostomy: A two years review. *Asian J Ophthalmol*. 2018; 16: 179-185.
8. Ali ME, Memon MD, Sherif SE, Tarek MA. Study of the effect of different designs of nasal mucosal and lacrimal sac flaps on success rate of external dacryocystorhinostomy. *J Egypt Ophthalmol Soc*. 2017; 110: 14-21.
9. Takahashi Y, Mito H, Kakizaki H. External dacryocystorhinostomy with and without double mucosal flap anastomosis: comparison of surgical outcome. *J Craniofac Surg*. 2015; 26(4): 1290-3.
10. Sathish K, Prakash DN, Shubrata SH, et al. Comparative study of external DCR with suturing of both anterior and posterior flaps versus anterior flap alone. *J Evolution Med Dent Sci*. 2015; 4(34): 5923-5.
11. Ratandeeep KA, Sharmistha B, Sasmita S. A Comparative study of external dacryocystorhinostomy using single flap, double flap and intra cystic implant (Pawar) dacryocystorhinostomy techniques. *Yuva J Medical Sci*. 2016; 2(1): 12-22.
12. Saiju R, Morse LJ, Weinberg D, Shrestha MK, Ruit S. Prospective randomized comparison of external Dacryocystorhinostomy with and without silicone intubation. *Br J Ophthalmol*. 2009; 93(9): 1220-22.
13. Zaman M, Babar TF, Saeed N. A review of 120 cases of dacryocystorhinostomies (Dupuy-Dutemps and Bourget Technique) *J Ayub Med Coll Abbottabad*. 2003; 15: 10-12.
14. Baldeschi L, Nardi M, Hintschich CR, Koornneef L. Anterior suspended flaps: A modified approach for external dacryocystorhinostomy. *Br J Ophthalmol*. 1998; 82: 790-2.
15. Burcu Dirim, Selam Yekta Sendul, Mehmet Demir et al. Comparison of Modification in Flap Anastomosis Pattern and skin incision types for external Dacryocystorhinostomy: Anterior- Only Flap Anastomosis with W Skin Incision versus Anterior and Posterior Flap Anastomosis with Linear Skin Incision. *Scientific World J*. 2015;
16. Mahmoud A Hassan, Mohamed H Badreldin, Tarek El- Nahriry et al. I shaped incision with mucosal flap preserving technique in endoscopic dacryocystorhinostomy. 2018; 34: 173-8.
17. Patel K, Magdum R, Sethia S, Lun A, Pradhan A, Misra RN. A clinico-bacteriological study of chronic dacryocystitis. *Sudanese J Ophthalmol*. 2014; 6(1): 1-5.
18. Grob SR, Campbell A, Lefebvre DR, Yoon MK. External versus endoscopic endonasal dacryocystorhinostomy. *Int Ophthalmol Clin*. 2015; 55(4): 51-62.
19. Tetikoglu M, Sagdik HM, Ozcura F, Aktas S. Assessment of anterior suspended flaps modification for external dacryocystorhinostomy. *J Craniofac Surg*. 2015; 26(3): 789-991.

### **ONLINE FIRST**

20. Lee MJ, Khwarg SI, Kim IH. Surgical outcomes of external dacryocystorhinostomy and risk factors for functional failure: a 10-year experience. *Eye*. 2017; 31(5):691-669.
21. Hussein M, Akhter S. DCR (Dacryocystorhinostomy) with or without intubation. *Pak J Med Res* 2005; 44:758
22. Advani RK, Haleopota FM, Shah SI. Indications and result of DCR with silicone tube intubation. *Pak J Ophthalmol* 2001; 17:60-2
23. Wenyan Peng, Bowei Tan, Xuanwei Liang. A Modified Preserved Nasal and Lacrimal Flap Technique in Endoscopic Dacryocystorhinostomy; article 6809 (2017)
24. Mohamed Al-Tahir AA. Flapless External Dacryocystorhinostomy: Do flaps really matter? *AAMJ*. 2012; 10(3):
25. Ranjan R, Rupam K, Kumar. Flapless external DCR: It is time to say good bye flaps. *Arch Nurs & Care*. 2019; 2(1):